

## Autologous Cultured Fibroblast Injection for Facial Contour Deformities: A Prospective, Placebo-Controlled, Phase III Clinical Trial

ROBERT A. WEISS, MD,<sup>\*†</sup> MARGARET A. WEISS, MD,<sup>\*†</sup> KAREN L. BEASLEY, MD,<sup>†‡</sup> AND GIRISH MUNAVALLI, MD<sup>\*†</sup>

---

**BACKGROUND** Previous data indicate that injections of autologous fibroblasts increase collagen formation, accompanied by a concomitant increase in thickness and density of dermal collagen.

**OBJECTIVE** The purpose of this study was to determine efficacy and side effects of autologous living fibroblast injections versus placebo in a randomized Phase III trial for the treatment of various facial contour defects.

**METHODS** This was a double-blind, randomized comparison of injectable living autologous fibroblast cells and placebo for the treatment of facial contour defects (N = 215). Live fibroblasts (20 million/mL) or placebo (the transport medium without living cells) were given as three doses administered at 1- to 2-week intervals. Efficacy evaluations were performed 1, 2, 4, 6, 9, and 12 months after the first injection.

**RESULTS** Living fibroblasts produced statistically significantly greater improvements in dermal deformities and acne scars than did placebo. The difference between live fibroblast injections and placebo achieved statistical significance at 6 months ( $p < .0001$ ). At 9- and 12-month follow-up, live fibroblast-treated patients continued to demonstrate benefit from treatment with response rates of 75.0 and 81.6%, respectively. No serious treatment-related adverse events were reported.

**CONCLUSIONS** Our results indicate that autologous fibroblast injections can safely and effectively produce improvements in rhytids, acne scars, and other dermal defects continuing for at least 12 months after injection.

*This study was funded by Isolagen Technologies, Inc., Exton, PA. Dr. Munavalli has ongoing research grants from Isolagen and is a consultant for Isolagen.*

---

Dermal fillers for the correction of facial contour deformities such as nasolabial folds, glabellar crease, deep wrinkles of the forehead, and acne scars have been in clinical use for almost three decades. Injectable bovine collagen was the first material successfully used as dermal filler,<sup>1</sup> and the armamentarium now includes synthetic and other protein-based materials. These products, however, have some limitations. For example, up to 6% of patients suffer hypersensitivity reactions to bovine collagen, which can manifest as granulomatous inflammation, necrosis, or abscess

formation.<sup>2,3</sup> Rare systemic complications have been reported.<sup>4-6</sup>

Bovine collagen corrections are temporary, because protein-based fillers are resorbed by tissue collagenases within weeks to months of injection.<sup>7-9</sup> Longer lasting synthetic fillers, such as hyaluronic acid, still carry a small risk of granulomatous allergic reactions, and injection technique can result in temporary surface elevations.<sup>10-16</sup> Problems with autologous tissues include requiring extensive surgical tissue-harvesting procedures.

*\*Department of Dermatology, Johns Hopkins University School of Medicine; †University of Maryland School of Medicine; ‡Maryland Laser, Skin, and Vein Institute, Baltimore, Maryland*

To overcome some of these limitations, an autologous living fibroblast culture technique was developed by Isolagen Technologies, Inc. (Exton, PA). This technique may safely produce sustained improvements in contour defects without surgery and virtually zero risk of hypersensitivity reactions. This method, termed the Isolagen therapy (IT) system, involves a small postauricular punch biopsy, which is used to create an autologous fibroblast cell line through a specific culturing process. These numerically multiplied living autologous fibroblasts are then injected directly into the patient's dermis where it is believed these cells create a continuous protein repair system. Recent studies have demonstrated objectively and subjectively measured improvements in facial contour defects lasting at least 12 to 48 months.<sup>17,18</sup> Histologic analysis in these studies demonstrated that fibroblast injections increase collagen formation, accompanied by a concomitant increase in thickness and density of dermal collagen. This process has not been associated with an inflammatory response. The purpose and design of this study were to determine efficacy and side effects in a randomized Phase III trial utilizing autologous living fibroblast injections versus placebo compared in the treatment of eight different facial contour defects.

### Materials and Methods

This IRB-approved study enrolled 158 patients, of which 151 were treated, at 10 US sites. The study population consisted of patients with facial contour deformities including acne scars of boxcar and craterform type; nasolabial and melolabial folds; periorbital, vermilion, and glabellar lines; forehead wrinkles; and other defects. Patients were randomized in a double-blinded 3:1 fashion to live fibroblast cell or placebo injections and then underwent a postauricular skin biopsy. The skin sample was sent to an Isolagen Technologies, Inc., laboratory where the fibroblasts were selected, cultured, and multiplied over a several-week period using a proprietary process. This yielded approximately 20 million cells in 1 mL for injection. Injections with live fibroblasts or placebo (the transport medium without living

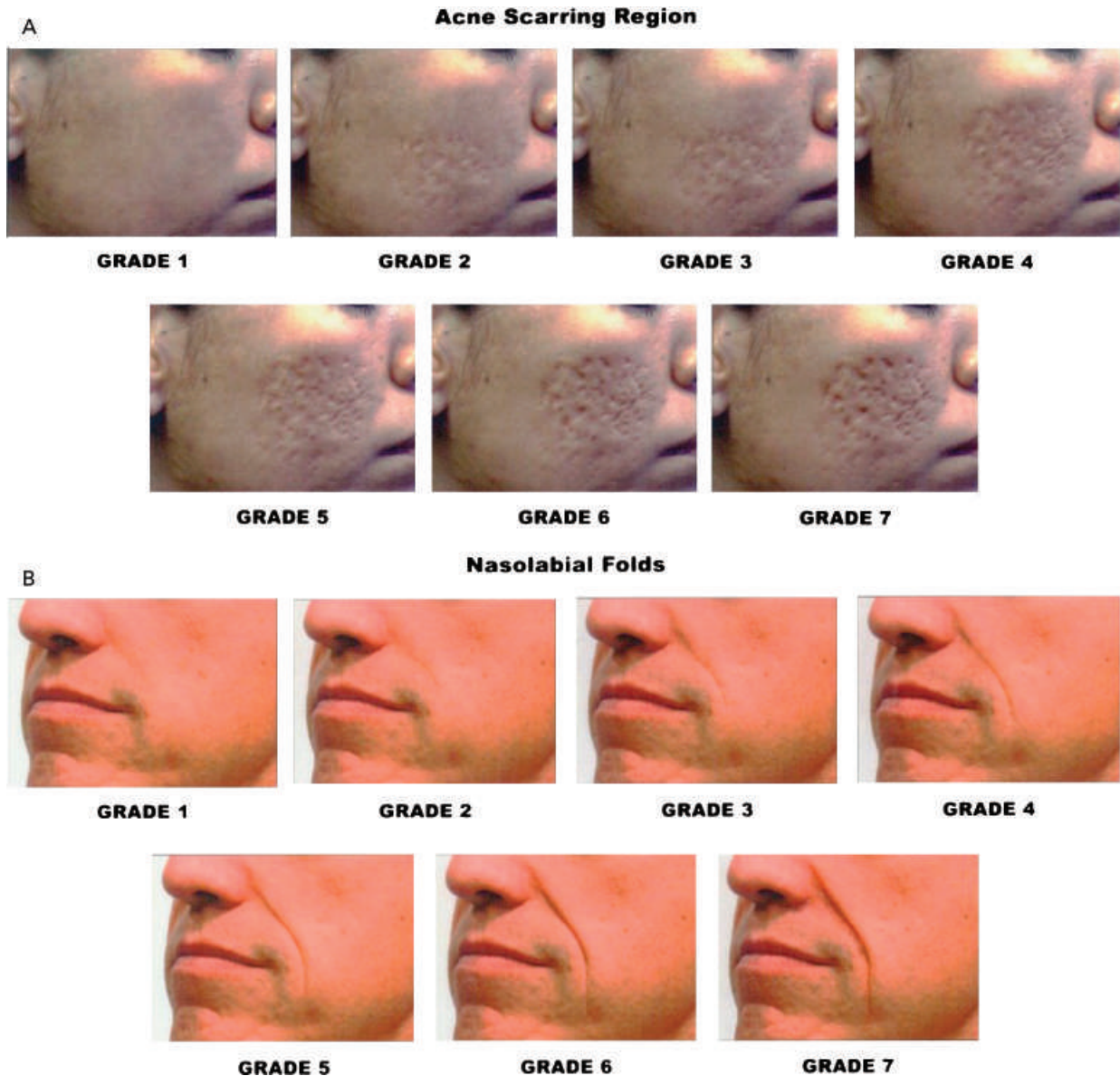
cells) were given as three doses administered at 1- to 2-week intervals. These intervals were randomized. The injections were given using the threading technique with a 30-gauge needle, without the use of injected or topical anesthetics. Application of cold was permitted.

Efficacy evaluations were performed 1, 2, 4, 6, 9, and 12 months after the first injection. The primary efficacy end point was a 2-point shift in at least one treated area using a standardized 7-point photo-guide, as determined by the investigator during a live assessment of the patient 4 months after beginning treatment (Figure 1). Patients achieving this shift were considered responders. After the 6-month evaluation occurred, patients were unblinded to treatment. Those who received live fibroblast injections returned for evaluation at 9 and 12 months. Placebo-treated patients were given the option of crossing over to active treatment (all of whom requested active treatment at our site). All fibroblast-treated patients including crossover were to be followed for a full 12 months after the first injection.

Fisher exact test was used to evaluate the primary end point of successful response, as gauged by the investigator assessment, between treatment groups and a *p* value of less than .05 was considered statistically significant.

### Results

Of the 151 treated patients, 6 were excluded from the evaluable population for several reasons: receiving additional cosmetic treatments and procedures during the study, voluntary patient withdrawal, or investigator withdrawal. Of the 145 total evaluable patients, 106 were treated with live fibroblast injections, and 39 with placebo. The population was 89.7% women and 10.3% men. Mean age at the time of the first injection was 46.7 (SD,  $\pm$  10.5) years. Caucasians comprised 92.4% of the study population; 4.8% of patients were Asian, 1.4% were Hispanic, and 1.4% were African-American. Treated sites are described in Table 1.



**Figure 1.** Standardized photoguides used for judging efficacy. (A) Acne scars. (B) Nasolabial lines. Patients were considered responders if there was a 2-point shift as determined by the investigator during a live examination.

The proportion of responders was dramatically higher in the Isolagen live fibroblast treatment group than in the placebo group throughout the controlled study (Figure 2). At 1-month follow-up, the responder rate among fibroblast-treated patients was 54.4% versus 30.8% with placebo. At 2 months, the fibroblast responder rate increased to 77.3%, whereas the placebo responder rate remained relatively the same at 34.3%. At 4 months, rates were 75.5% versus 34.3%, and at 6 months, 81.0% ver-

sus 36.4%. The difference between live fibroblast injections and placebo achieved statistical significance at 6 months ( $p < .0001$ ). The short-term improvements seen with placebo injections were mostly attributable to temporary subcisionlike effects induced by dissection with transport media injections. At 9- and 12-month follow-up, live fibroblast-treated patients continued to demonstrate benefit from treatment with response rates of 75.0 and 81.6%, respectively.

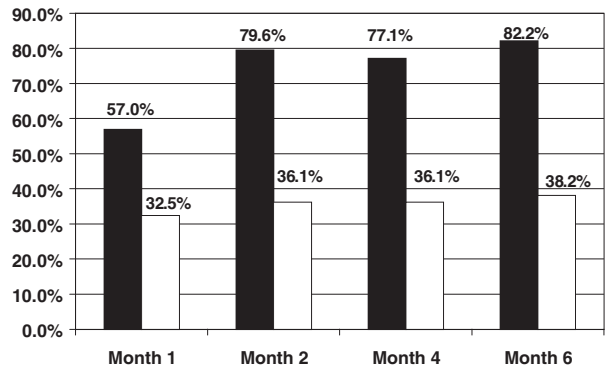
**TABLE 1. Facial Deformities Treated with at Least One Dose of Injectable Fibroblasts**

Treated sites	Number of patients*
Facial scars	50
Nasal labial folds	95
Melolabial folds	10
Periorbital lines	9
Vermilion lines	31
Glabellar lines	11
Forehead wrinkles	5
Other†	24

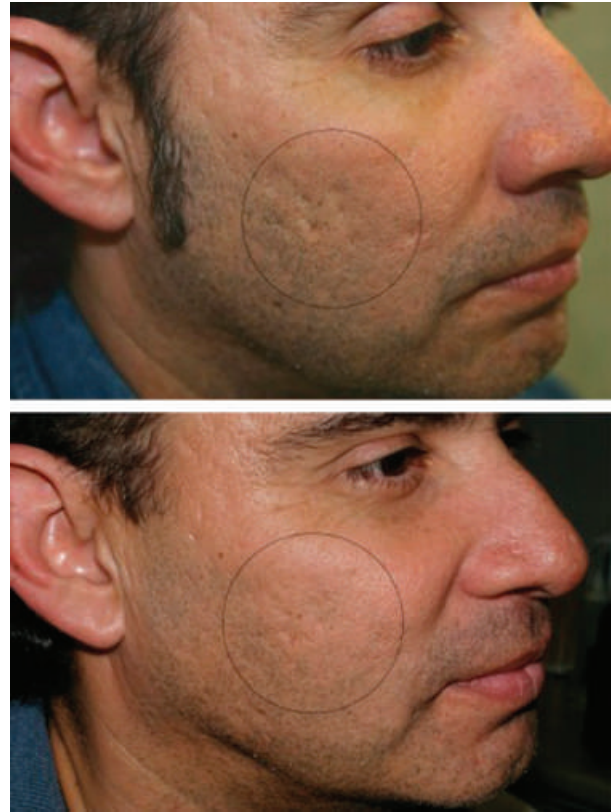\*Most patients were treated in multiple areas and are therefore counted in multiple areas.  
 †The "others" include lower corner of mouth (7 patients); chin (6 patients); lip scar (5 patients); and eyes, nasal scar, cheek, temple, trough, and spider bite (1 patient each).

The clinical effect of fibroblast injection was particularly pronounced among patients treated for acne scars (Figure 3). In this subgroup, the response rate at 6-month follow-up was 48.4%, compared with 7.7% for placebo, a statistically significant difference ( $p < .05$ ).

At 4-month follow-up, 87 patients with nasolabial folds and, at 6 months, 84 patients with nasolabial folds had visible improvement. The response rate at the 4-month visit was 34.8% for patients treated with live fibroblast injections versus 9.5% for placebo. At 6 months, the rates were 42.2% versus 10.0%, respectively. The differences at both time points achieved statistical significance ( $p < .05$ ).



**Figure 2.** Percentage of responders by visit for all treatment areas. (■) Isolagen; (□) placebo.



**Figure 3.** Improvement in acne scarring following a series of three live fibroblast injections 2 weeks apart at 6-month follow-up. Treated areas are circled.

The safety profile of live fibroblast injections was also favorable. The majority of the reported adverse events were either unrelated to or unlikely to be related to study treatment and were seen in a similar proportion of patients in both study arms. Of the adverse events considered by an investigator to be possibly, probably, or definitely related to live fibroblast injections, one case of edema lasting for several hours at the injection site of one patient was considered significant. No serious adverse events considered related to the study treatment were reported. Routine laboratory results including hematology and chemistry were unremarkable and showed no abnormalities or definitive trends.

**Conclusions**

Our results indicate that autologous fibroblast injections can safely produce improvements in rhytids,

acne scars, and other dermal defects. The injections are made superficially in the dermis and are for dermal remodeling. This is not for deep furrows because it is not a volume filler. The results are consistent with those of Watson and colleagues<sup>17</sup> who reported reductions in large rhytid and depressed facial scars of 10% to 85% as measured by profilometry. Boss and colleagues<sup>9</sup> reported high rates of short- and long-term patient satisfaction with the Isolagen process (92% at 12 months and 70% at 36–48 months), as well as continuing correction during the entire observation period. As in these studies, our findings are similar indicating that autologous fibroblast injection is safe and efficacious in the treatment of wrinkles and acne scars.

Dermal fillers have been in clinical use since the late 1970s. Bovine collagen was the original filler of choice, but dermal filler technology has greatly improved with the addition of synthetic materials such as hyaluronic acid derivatives.<sup>19,20</sup> Other fillers still commercially available are protein-based fillers such as purified human dermal tissue and other synthetic materials such as purified polymethylmethacrylate suspended in bovine collagen.<sup>8,20–26</sup> Although these technologies can safely and effectively repair dermal defects, they can be associated with rare hypersensitivity and allergic reactions, swelling, bruising, granulomatous foreign body formation, infection, and malalignment.<sup>3,4,6,10–13,15,27–31</sup> In the case of some synthetic products, results may not be evident for up to 2 years after implantation. Results with animal-based collagen injections may be more immediate but are transient, being measured in weeks, because animal collagen is quickly resorbed, although reactions have been described as lasting as long as 24 months with bovine collagen.<sup>2,8</sup> Hyaluronic acid fillers may last 6 to 12 months or even longer but also require reinjection at regular intervals to maintain results.<sup>19</sup>

The use of autologous materials has the potential to circumvent some of these limitations. For example, autologous fat may obviate the risk of hypersensi-

tivity responses. Unfortunately, as is the case with bovine collagen, autologous fat is easily resorbed and, importantly, fat must be harvested using a more advanced technique.<sup>17,32,33</sup> Another process previously on the market utilized intact autologous collagen fibers (Dermalogen) from a patient's own dermis. But due to a complicated procedure required to extract the collagen fibers, this procedure is no longer being performed.<sup>8,18</sup>

The Isolagen autologous cell system does not require extensive surgical extraction—a small biopsy is performed at a nonvisible site, typically postauricular in the fold, and the fibroblast cells cultured and multiplied in the millions. Unused cells can be stored in liquid nitrogen for new and repeat procedures. Our initial experience with the autologous living fibroblast injection process indicates that it is likely capable of producing ongoing improvements in facial contour defects without the hypersensitivity complications and harvesting challenges associated with other treatments. Numerous clinical trials are in progress to corroborate these results and reconfirm the longevity of clinical improvement in rhytids and scars.

*Acknowledgments* We thank and express gratitude to the Isolagen Study Group, which includes all the primary investigators for this study: Suzanne Bruce, MD, Houston, Texas; Greg Chernoff, MD, Indianapolis, Indiana; Stephen Krant, MD, La Jolla, California; David McDaniel, MD, Virginia Beach, Virginia; Henry Mentz, MD, Houston, Texas; Jeffrey Popp, MD, Omaha, Nebraska; Stephen Senft, MD, Bethlehem, Pennsylvania; Nancy Silverberg, MD, Newport Beach, California; and Deborah Watson, MD, San Diego, California. We thank Dr. Marie Lindner, Isolagen Medical Director, for collecting and organizing the data.

## References

1. Knapp TR, Kaplan EN, Daniels JR. Injectable collagen for soft tissue augmentation. *Plast Reconstr Surg* 1977;60:398–405.
2. Hanke CW, Higley HR, Jolivet DM, et al. Abscess formation and local necrosis after treatment with Zyderm or Zypplast collagen implant. *J Am Acad Dermatol* 1991;25:(2 Pt 1):319–26.

3. Swanson NA, Stoner JG, Siegle RJ, Solomon AR. Treatment site reactions to Zyderm collagen implantation. *J Dermatol Surg Oncol* 1983;9:377-80.
4. Mullins RJ, Richards C, Walker T. Allergic reactions to oral, surgical and topical bovine collagen. Anaphylactic risk for surgeons. *Aust N Z J Ophthalmol* 1996;24:257-60.
5. Heise H, Zimmermann R, Heise P. Temporary granulomatous inflammation following collagen implantation. *J Craniomaxillofac Surg* 2001;29:238-41.
6. Garcia-Domingo MI, Alijotas-Reig J, Cistero-Bahima A, et al. Disseminated and recurrent sarcoid-like granulomatous panniculitis due to bovine collagen injection. *J Invest Allergol Clin Immunol* 2000;10:107-9.
7. Sclafani AP, Romo T III. Injectable fillers for facial soft tissue enhancement. *Facial Plast Surg* 2000;16:29-34.
8. Sclafani AP, Romo T III, Parker A, et al. Homologous collagen dispersion (dermalogen) as a dermal filler: persistence and histology compared with bovine collagen. *Ann Plast Surg* 2002;49:181-8.
9. Boss WK Jr, Usal H, Fodor PB, Chernoff G. Autologous cultured fibroblasts: a protein repair system. *Ann Plast Surg* 2000 May;44:536-42.
10. Raulin C, Greve B, Hartschuh W, Soegding K. Exudative granulomatous reaction to hyaluronic acid (Hylaform). *Contact Dermatitis* 2000;43:178-9.
11. Honig JF, Brink U, Korabiowska M. Severe granulomatous allergic tissue reaction after hyaluronic acid injection in the treatment of facial lines and its surgical correction. *J Craniofac Surg* 2003;14:197-200.
12. Rongioletti F, Cattarini G, Sottofattori E, Rebora A. Granulomatous reaction after intradermal injections of hyaluronic acid gel. *Arch Dermatol* 2003;139:815-6.
13. Klein AW. Granulomatous foreign body reaction against hyaluronic acid. *Dermatol Surg* 2004;30:1070.
14. Lombardi T, Samson J, Plantier F, et al. Orofacial granulomas after injection of cosmetic fillers. Histopathologic and clinical study of 11 cases. *J Oral Pathol Med* 2004;33:115-20.
15. Sidwell RU, Dhillon AP, Butler PE, Rustin MH. Localized granulomatous reaction to a semi-permanent hyaluronic acid and acrylic hydrogel cosmetic filler. *Clin Exp Dermatol* 2004;29:630-2.
16. Soparkar CN, Patrinely JR, Tschen J. Erasing restylane. *Ophthalm Plast Reconstr Surg* 2004;20:317-8.
17. Watson D, Keller GS, Lacombe V, et al. Autologous fibroblasts for treatment of facial rhytids and dermal depressions: a pilot study. *Arch Facial Plast Surg* 1999;1:165-70.
18. Boss WK Jr, Usal H, Chernoff G, et al. Autologous cultured fibroblasts as cellular therapy in plastic surgery. *Clin Plast Surg* 2000;27:613-26.
19. Narins RS, Brandt F, Leyden J, et al. A randomized, double-blind, multicenter comparison of the efficacy and tolerability of Restylane versus Zyplast for the correction of nasolabial folds. *Dermatol Surg* 2003;29:588-95.
20. Lemperle G, Morhenn V, Charrier U. Human histology and persistence of various injectable filler substances for soft tissue augmentation. *Aesthetic Plast Surg* 2003;27:354-66.
21. Bergeret-Galley C, Latouche X, Illouz YG. The value of a new filler material in corrective and cosmetic surgery. *DermaLive and DermaDeep*. *Aesthetic Plast Surg* 2001;25:249-55.
22. Sclafani AP, Romo T III, Parker A, et al. Autologous collagen dispersion (Autologen) as a dermal filler: clinical observations and histologic findings. *Arch Facial Plast Surg* 2000;2:48-52.
23. Sclafani AP, Romo T III, Jacono AA, et al. Evaluation of acellular dermal graft in sheet (AlloDerm) and injectable (micronized AlloDerm) forms for soft tissue augmentation. Clinical observations and histological analysis. *Arch Facial Plast Surg* 2000;2:130-6.
24. Sclafani AP, Romo T III, Jacono AA. Rejuvenation of the aging lip with an injectable acellular dermal graft (Cymetra). *Arch Facial Plast Surg* 2002;4:252-7.
25. DeVore DP, Hughes E, Scott JB. Effectiveness of injectable filler materials for smoothing wrinkle lines and depressed scars. *Med Prog Technol* 1994;20:243-50.
26. DeVore DP, Scott JB, Nordquist RE, et al. Rapidly polymerized collagen gel as a smoothing agent in excimer laser photoablation. *J Refract Surg* 1995;11:50-5.
27. Moscona RR, Bergman R, Friedman-Birnbaum R. An unusual late reaction to Zyderm I injections: a challenge for treatment. *Plast Reconstr Surg* 1993;92:331-4.
28. Overholt MA, Tschen JA, Font RL. Granulomatous reaction to collagen implant: light and electron microscopic observations. *Cutis* 1993;51:95-8.
29. Maas CS, Papel ID, Greene D, Stoker DA. Complications of injectable synthetic polymers in facial augmentation. *Dermatol Surg* 1997;23:871-7.
30. Lupton JR, Alster TS. Cutaneous hypersensitivity reaction to injectable hyaluronic acid gel. *Dermatol Surg* 2000;26:135-7.
31. Soparkar CN, Patrinely JR. Managing inflammatory reaction to Restylane. *Ophthalm Plast Reconstr Surg* 2005;21:151-3.
32. Scarborough DA, Schuen W, Bisaccia E. Fat transfer for aging skin: technique for rhytids. *J Dermatol Surg Oncol* 1990;16:651-5.
33. Illouz YG. Present results of fat injection. *Aesthetic Plast Surg* 1988;12:175-81.

---

Address correspondence and reprint requests to: Robert A. Weiss, MD, 54 Scott Adam Road, Suite 301, Hunt Valley (Baltimore), MD 21030, or e-mail: rweiss@mdslv.com.